

## ***Clinical applications of Er:YAG lasers in periodontal therapy***

By Professor Tzi Kang Peng, DDS, MS, PhD

# ER:YAG LASERS

*“Clinical studies and research indicates that Erbium lasers are indicated for all oral tissues...It provides dentists with the capability to perform a wide range of clinical procedures in periodontics with improved patient outcomes, less trauma, reduced postoperative complications and in some cases, without the need for LA...”*

## HIGH TECH DENTISTRY

Using lasers for the treatment of periodontal disease is particularly indicated for patients with debilitating medical conditions. By receiving laser periodontal treatment, patients often have no need for local anesthesia in phase I of periodontal therapy. In this article, the potential of the new Er: YAG laser (LiteTouch, Syneron) was assessed in various periodontal procedures including gingivectomy, reduction or elimination of perio pockets, flap surgery and crown lengthening. The Er: YAG laser is safe and more controlled when used to cut soft and osseous tissues but does not provide good haemostatic properties in aggressive periodontal surgery.

### Introduction

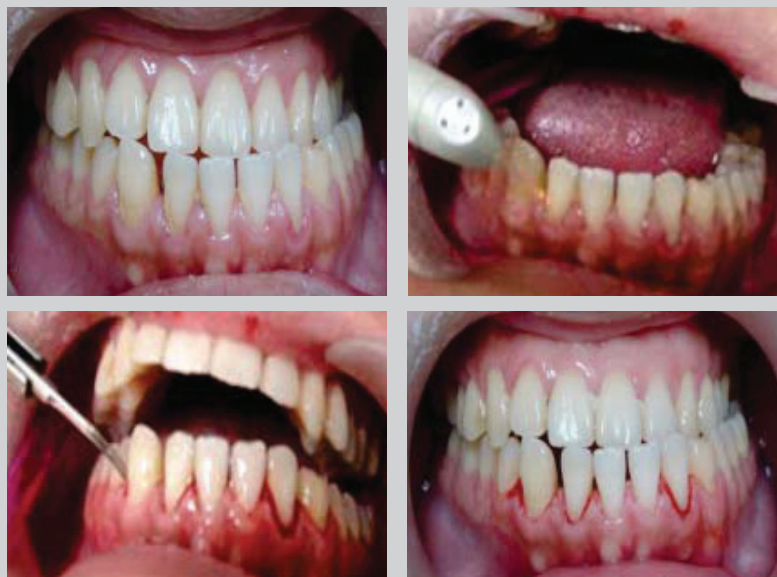The use of lasers in clinical dentistry is becoming more commonplace. It is even suggested that clinical dentistry is undergoing a paradigm shift thanks to advanced laser technology.<sup>1</sup> This is particularly thanks to the Erbium family of lasers, including the Er:YAG (2940nm) and Er, Cr:YSGG (2780 nm) which have very similar properties, and provide excellent absorption in the water of soft and hard tissue and hydroxyapatite.<sup>2,3</sup> Erbium lasers contour osseous structures without damaging tooth structure by using a cooling water spray for hard tissue procedures that can be switched off for soft tissue procedures.<sup>4</sup>

Different types of lasers have been used in non-surgical periodontal treatment as an alternative or as an adjunct to mechanical scaling and root planing.<sup>5-8</sup> A 5-year clinical study indicated that Er:YAG laser-assisted periodontal flap surgery on single-rooted teeth results in greater periodontal depth reduction and gains in clinical attachment as compared to conventional treatment with the modified Widman flap procedure.<sup>9</sup>

Clinical studies and research indicates that Erbium lasers are indicated for all oral tissues and absorption in the water of soft and hard tissue. Erbium lasers have the ability to remove caries in enamel and dentin with greatly reduced local anesthetic or without anesthetic at all.<sup>2,10-12</sup> The Erbium laser light can be used in the periodontal field as an adjunct to conventional therapy (phase I)<sup>13,14</sup> or as a tool in periodontal surgery,<sup>9,17</sup> because the periodontium consists of both soft and hard tissue. It provides dentists with the capability to perform a wide range of clinical procedures in periodontics with improved patient outcomes, less trauma, reduced postoperative complications and in some cases, again without the need for LA. The Er:YAG laser photons distinctively target the chromophore of molecular water within calcified tissue, but not the calcified structure itself.

In 2006, Syneron Medical in Israel developed the new LiteTouch Er:YAG laser for dental use. In this unit, the laser is wholly contained within the handpiece, negating the need for a fiber-optic delivery system.

The purpose of this article is to describe the use of this Er:YAG laser in various periodontal procedures including scaling and root planing, gingivectomy, pocket elimination and flap surgery. With recent advances in this laser direct delivery system available today, it seems that dental practitioners can now use lasers on both hard and soft tissues with safety and predictability in different directions.



**Case 1 (LtoR)** Figure 1a. Chronic gingivitis; Figure 1b. Soft mode: Initial setting. Removal of inflamed gingival tissue with 1.0 w, 100mJ, 10Hz. Hard Mode: Removal of inflamed gingival tissue and calculus with 4.w 200mJ, 20 Hz without local anesthesia; Figure 1c. Removal of subgingival calculus by ultrasonic scaling. Figure 1d. Wound after removal of inflamed gingival tissue and subgingival calculus with Er:YAG laser.

## Patient selection and evaluation

Patients who presented at our clinic for laser periodontal treatment underwent a full and comprehensive periodontal examination including medical and dental history, periodontal charting and radiographs including PAs and an OPG. The first case was to study the ability of the Er:YAG laser to remove inflamed gingival tissue and subgingival calculus in a patient with chronic gingivitis without phase I periodontal therapy. All of the other cases have completed phase I periodontal therapy. The interval of maintenance including reinforcement of oral hygiene, interdental brushing, flossing or laser treatment varies from every few weeks, one month and three months to every six months based on patient needs and concerns.

## Laser operation

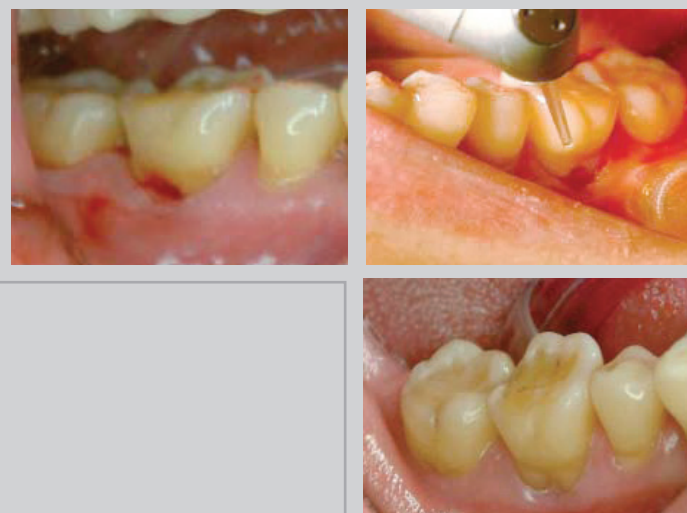The laser energy from the Er:YAG laser is in the infrared spectrum. The laser beam is directed at the target tissue on the medium setting. In this laser, the photon amplification occurs through a medium of heterogeneous crystals (YAG). This laser emits photons at a wavelength of 2,940nm and a pulse duration of 0.5-1.0 microsecond in the repetition rate that can vary from 10Hz to 50Hz. During surgical procedures, the power output is 1.0W-8.4W, yielding an energy density of 100-700mJ. The sapphire tip has a diameter of 600, 800, 1000 or

1300µm. During the surgical procedure, the sapphire cutting tip is approximately 2mm from the target tissue. Cutting soft/osseous tissues is a complex interaction of laser energy with water in the tissues (hydrophotronics). Thus, the amount of laser energy needed to produce the desired results varies depending on the tissue involved.

## Clinical case presentations

### Case 1. Chronic gingivitis: Removal of inflamed gingival tissue and calculus

The patient presented with mild chronic gingivitis on the lower anterior teeth (Figures 1a-d). A comparison was made to evaluate the effect of removing subgingival calculus and inflamed gingival tissue with the laser or ultrasonic scaling without topical local anesthesia. The laser ablates and removes inflamed soft tissue by selectively removing a few cell layers and removes the subgingival calculus too. The ultrasonic scaler only removes subgingival calculus. It seems that use of this laser allows us to achieve the successful results that had been previously achieved only by phase I periodontal therapy. The protocol usually includes the reinforcement of oral hygiene instruction with interdental brushing and flossing followed by laser treatment. The gold standard for successful treatment of periodontal disease is defined as a maintenance or gain of clinical techniques.



**Case 2 (LtoR)** Figure 2a. Moderate periodontitis on #46 (grade I invasion); Figure 2b. Soft mode: Removal of inflamed gingival tissue with 1.0W, 100MJ, 10Hz. Hard Mode: Removal of inflamed gingival tissue, subgingival calculus and crestal bone along the root and furcation with 4.0W 200mJ, 20Hz without local anesthesia; Figure 2c. Wound healing with adequate attachment of gingival tissue after just two weeks.

The inflamed soft tissue was removed with a sapphire tip (800 micron), with initial settings of 10Hz and 100MJ (1.0W), contact in soft mode. Then the inflamed soft tissue and subgingival calculus were removed with the same sapphire tip with final settings of 20Hz and 200MJ (4.0W), slight non-contact and contact interchangeably, in hard tissue mode. If anesthetic had not been given, lower initial settings and slight contact would have been used.

### Case 2. Furcation invasion Grade I: Removal of inflamed gingival tissue and osseous architecture with laser

A healthy 55-year old woman was referred to our clinic for periodontal treatment. The patient had moderate periodontitis on #36 (Figures 2a-c) and #46 (Figures 2d-f) and presented with pain and swelling that she had complained of for years. The inflamed soft tissue was removed by using a sapphire tip (800 micron) with initial settings of 10Hz and 100MJ (1.0W) in contact soft mode. Then the inflamed soft tissue and osseous tissue were removed by using the same sapphire tip with final settings of 20Hz and 200MJ (4.0W) in non-contact hard mode. At initial settings, the tip was moved along the crest of gingival tissue to the bottom of the pocket with overlapping strokes as if probing the pocket. For ablation of bone, the same diameter tip is used for removal of crestal bone along the root and furcation to allow secondary healing of gingival tissue in the

## HIGH TECH DENTISTRY

closed flap surgery. No local anesthetic injection was given. It seems that a minor reduction in the amount of osseous structure by way of closed flap surgery with the laser may yield excellent results with adequate attached buccal gingival tissue and topical local anesthetic.

### Case 3. Advanced periodontitis with grade III furcation invasion: Removal of inflamed gingival tissue and subgingival calculus with Er:YAG laser

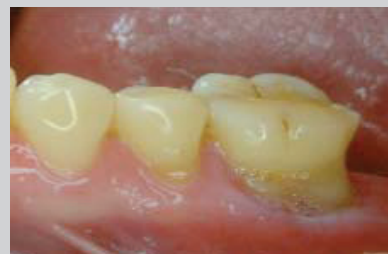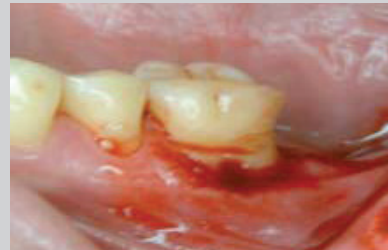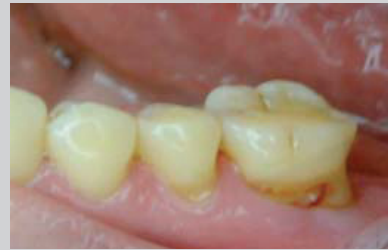An 87-year old male with coronary artery disease and taking anticoagulants presented with advanced periodontitis, traumatic occlusion and pain, swelling and bleeding (Figures 3a-d). Extraction of teeth with advanced periodontitis on #25-27 and completion of porcelain crown and bridge on #15-25 were performed to correct the traumatic occlusion caused by loosening of upper teeth. With the Er:YAG laser, further periodontal therapy was executed on the lower dentition without local anesthesia. The inflamed soft tissue was removed using a sapphire tip (800 micron), with initial settings of 10Hz and 100MJ (1.0W), contact in soft mode. The inflamed soft tissues were removed by using the same sapphire tip with settings of 20Hz and 100MJ (2.0W), and then 20Hz, 200MJ (4.0W), contact in hard mode. For removal of granulation tissue, subgingival calculus and contouring of bone, the 1000 micron tip was used non-contact in hard mode. For osseous recontouring, the tip was moved along the margin of the bone around the root and furcation, allowing secondary healing of gingival tissue in the closed flap surgery. Erbium lasers do not provide good hemostasis during closed flap surgery but may yield better results with a physiologic contour of periodontium after one month. In this case, the patient asked for no local anesthesia.

### Case 4. Advanced Periodontitis: Flap operation to remove inflamed gingival tissue, subgingival calculus and osseous recontouring with Er:YAG laser

A 45-year old woman with advanced periodontitis presented (Figures 4a-h). The treatment plan for this patient was suggested as follows:

- Phase I treatment: Oral hygiene instruction and scaling and root planning; and
- Phase II: Flap surgery with laser.

With the Er:YAG laser, further periodontal therapy was executed on all dentition in open flap surgery with local anesthesia. The procedure was started with a vertical incision using a sapphire tip (800 micron), at initial settings of 10Hz and 100MJ (1.0W), contact in soft mode.



**Case 2** (LtoR) Figure 2d. Moderate periodontitis on #46 (grade I invasion); Figure 2e. Soft mode: Removal of inflamed gingival tissue with 1.0W, 100MJ, 10Hz. Hard Mode: Removal of inflamed gingival tissue, subgingival calculus and crest bone along the root and furcation with 4.0w 200mJ, 20Hz without local anesthesia; Figure 2f. Wound healing with adequate attached gingival tissue after two weeks.

Then crest incision was made along the crest of the gingivae. The inflamed soft tissues were removed by using the same diameter sapphire tip with settings of 20Hz and 100MJ (2.0W), and then 20Hz, 200MJ (4.0W), contact in hard mode. For removal of granulation tissue and subgingival calculus and contouring of bone, the 1000 micron diameter tip was used in non-contact hard mode. For osseous recontouring, the tip was moved along the margin of the bone around the root and furcation in open flap surgery. Again, Erbium lasers do not provide good hemostasis in open flap surgery but may yield better result with a physiologic contour of periodontium after a month. In this case, the patient had asked for further treatment that involved a full mouth reconstruction combined with mini dental implants after extraction of teeth on #36, 37 and 46. The porcelain crown and bridge on 17-25 and 37-47 is fixed with MDI mini-implants.

### Case 5. Moderate to advanced periodontitis with traumatic occlusion and convex profile: Crown lengthening and open flap to remove granulation tissue, subgingival calculus and osseoplasty and osseotomy with Er:YAG

A 52-year old woman presented with moderate to advanced periodontitis on the upper dentition, unstable temporary crown and bridge on 12-22 and loosening on 27 (Figures 5a-h). The treatment plan for this patient was suggested as follows:

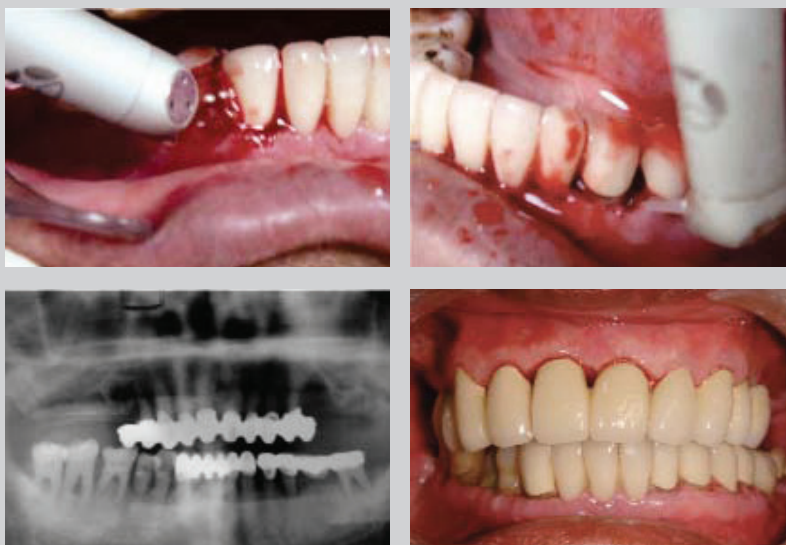
- Phase I: Oral hygiene instruction and scaling and root planning; and
- Phase II: Crown lengthening and periodontal therapy during open flap with Er:YAG laser.

The patient presented with unstable temporary crown and bridge on #12-22, a residual root on 22 and moderate to advanced periodontitis. This patient also had a convex profile with exostoses along the facial surface of the maxillary alveolus on 14-24. With the Er:YAG laser, periodontal therapy was performed to remove the inflamed soft tissue following the previous described settings. Ablation of buccal exostosis of 14-25 was completed with a 1300 micron diameter tip, non-contact in hard mode using an open flap technique. The procedure was started with a vertical incision made using a sapphire tip (800 micron) at initial settings of 10Hz and 100MJ (1.0W), contact in soft mode. Then crest incision was made along the crest of the gingivae. The inflamed soft tissues were removed using the same diameter sapphire tip with settings of 20Hz and 100MJ (2.0W), and then 20Hz, 200MJ (4.0W), contact in hard

mode. For removal of granulation tissue, subgingival calculus and contouring of bone, the 1000 micron diameter tip was used, non-contact in hard mode. For osseous recontouring, the tip was moved along the bone margin around the root. Further removal of exostosis along the facial surface of the maxillary alveolus was performed using a 1300 micron sapphire tip with settings of 20Hz, 400MJ (8.0W) and then recontouring of residual exostosis using the same tip with settings of 40Hz, 200MJ (8.0W). Finally, smoothing of the facial aspect of the maxillary alveolus was made using a bone file. After these procedures were completed, the gums are replaced back against the teeth and anchored using stitches. Crown lengthening on 12-24 was performed to expose the residual root on 22. The alveolar architecture mimics the restorative margin 3.0mm apically, allowing for a biologic width restoration to a normal crest position. The definitive porcelain crown and bridge on 15-25 was completed after laser periodontal therapy and crown lengthening. Further dental implant placement with a sinus lift was completed. Crown lengthening procedures, both for aesthetic improvement and additional tooth structure for restoration placement, also demonstrate the laser's precision. The tissue removal must be carefully planned so that biological width is maintained.

### Discussion and conclusion

Controlled clinical studies and case reports suggest that non-surgical and surgical periodontal therapy with an Er:YAG laser leads to significant gains in clinical attachment.<sup>5-9</sup> It is suggested that the effectiveness of the Er:YAG laser in SRP and in reducing subgingival



**Case 3** (LtoR) Figures 3a and 3b. Soft mode: Removal of inflamed gingival tissue with 1.0w, 100MJ, 10Hz; Hard Mode: Removal of inflamed gingival tissue, subgingival calculus and bone along the root and furcation with 2.0W, 100MJ, 20Hz and then 4.0, 200mJ, 2 Hz without local anesthesia; Figure 3c. Radiograph revealed advanced periodontitis with porcelain crown and bridge on #15-25, 37-43, and #34-37, 33-43; Figure 3d. Wound healing with adequate attached gingival tissue after two weeks

## HIGH TECH DENTISTRY

bacterial loads were noted.<sup>7</sup> A laser setting used in this article differed from the 5-year clinical trial reported by Gaspirc B9 and Skaleric.<sup>8</sup> These studies indicated that the renewal of biocompatibility of periodontal diseased root surfaces with Er:YAG laser radiation might enhance new attachment due to decreased bacterial loads within the pocket. In laser-tissue interaction, absorption occurs because of the presence of free water molecules, proteins, pigments and other organic matter. Laser light that is well absorbed by water (Er,Cr:YSGG, Er:YAG) is able to mechanically ablate enamel, dentin, and alveolar bone, while laser light not well absorbed by water and only absorbed by blood and tissue pigments (Diode, Nd:YAG), results in strong thermal reactions, such as carbonization, charring and melting of organic tissue. Therefore, the Erbium laser ablates hard tissue through "microexplosion" rather than heating the tissue, resulting in minimal thermal effects.

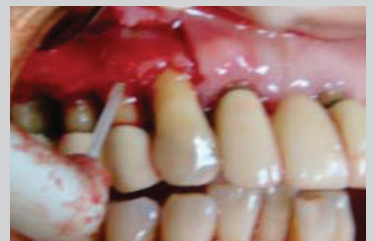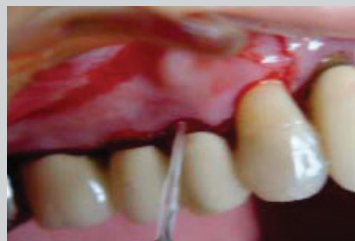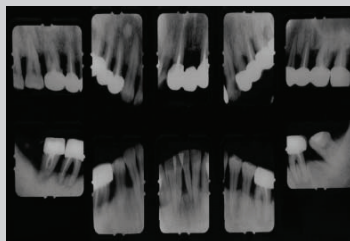
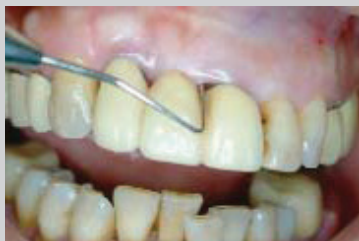Folwaczny et al indicated that the Er:YAG laser can remove considerable calculus, cementum or both and penetration into cementum increased significantly at 150 MJ/pulse.<sup>19</sup> Hand instrumentation may remove up to 264.4-343.3µm.<sup>20,21</sup> The laser at 100 MJ can remove cementum up to 386.12µm.<sup>19</sup> Aoki et al conflicted with these findings and indicated the maximum removal of cementum by a laser of 140µm.<sup>22</sup>

None of these cases presentations showed any detrimental outcome nor major thermal damage from the Er:YAG laser when used for debridement of root surfaces during periodontal treatment.

In this article, a case presented with a gummy smile and maxillary exostosis. The described simultaneous surgical intervention and prosthetic placement with the Er:YAG laser is applicable not only to specific cases such as this case, characterized by the existence of shortness of the original prosthetic crowns when part of the natural crown appears cervical to the prosthetic margin, but also to all cases of upper anterior sector treatment.

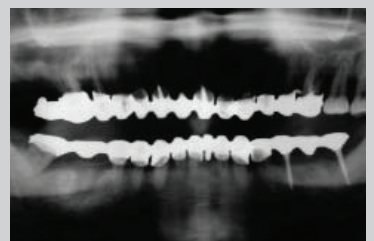
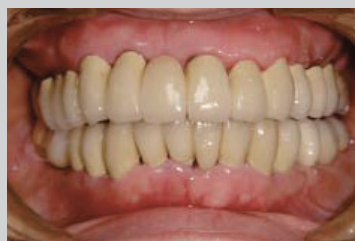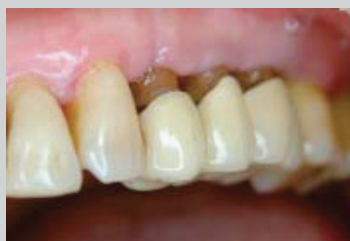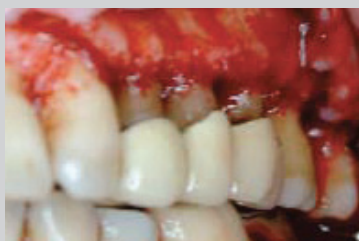This article highlights the associated periodontal therapy and demonstrated technique for the application of this laser in calculus removal, gingivectomy, pocket elimination, periodontal surgery and crown lengthening with an aesthetic profile. This Er:YAG laser can cut osseous structures by using a cooling water spray for hard tissue procedures that can be turned off for soft tissue surgery without the need for costly fibres or bulky articulated arms.

Further peer-reviewed clinical studies are needed, however, to establish the full potential of lasers in periodontal treatment and implant placement.



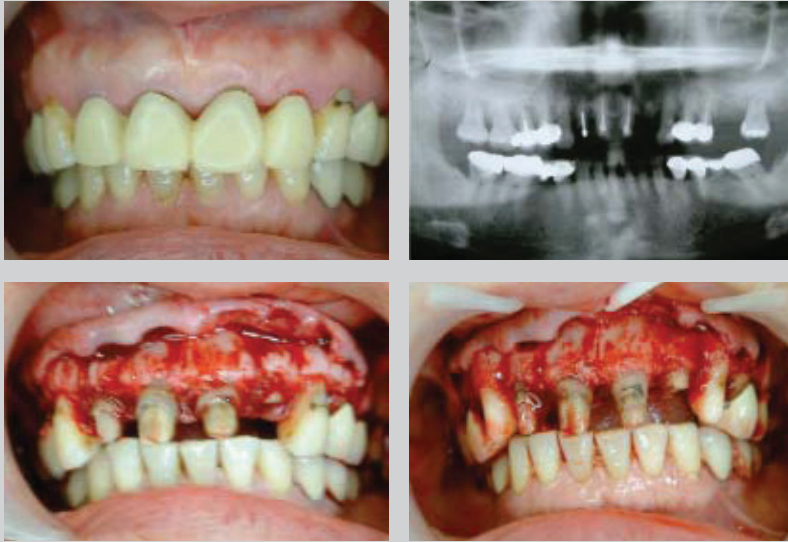**Case 4** (LtoR) Figure 4a. Advanced periodontitis with probing; Figure 4b. Radiograph revealed advanced bone loss; Figures 4c and 4d. Soft Mode: Initial vertical incision with 1.0W, 100mJ, 10Hz, and then crest incision with 2.0W,

100MJ, 10Hz. Hard Mode: Removal of inflamed gingival tissue and calculus with 4.0W 200mJ, 20Hz and then 6W, 300MJ, 20Hz.



**Case 4** (LtoR) Figure 4e. Removal of granulation tissue and bone recontouring with Er:YAG laser; Figure 4f. Wound healing at one month after laser periodontal open flap surgery; Figure 4g. Completion of full mouth reconstruction

with porcelain crown and bridge after laser periodontal treatment; Figure 4h. OPG revealed porcelain crown and bridge with MDI implant prosthesis on #35, 37.



**Case 5 (LtoR) Figure 5a.** Moderate to advanced periodontitis with buccal exostosis of maxillary alveolus; **Figure 5b.** Panograph revealed residual root on #22 in the bone, post on #12-21, moderate bone loss on #13-17, 23-25, advanced bone loss on #27; **Figure 5c.** Buccal exostosis and residual root on #22 were noted after laser incision. Soft Mode: Initial incision with 1.0W, 100MJ, 10Hz, and then 2.0W, 100, 10Hz. Hard Mode: Removal of inflamed gingival tissue and osseous recontouring/osstectomy with 4.0W 200MJ, 20 Hz and then 6.0W, 200MJ 20Hz; **Figure 5d.** Normal osseous architecture was noted after laser ablation of exostosis and crown lengthening.

## References

- Colluzzi DJ. Lasers, Types of Lasers and What Your Practice Needs: Laser Dentistry Made Easy and Profitable, www.dentaleconomics.com. 2007 April, 1-3.
- Glenn V.A. Erbium Lasers in Dentistry, Dent Clin N Am, 2004, 48:1017-1059.
- Dostalova T, Jelinkova H, Krejsa O, Hamal H. Evaluation of the surface changes in enamel and dentin due to possibility of thermal overheating induced by Erbium:YAG laser radiation. Scanning Microsc 1996; 10(1):285-90.
- Dean.D. B. Concepts in Laser Periodontal Therapy Using the Er,Cr:YSGG Laser, Academy of Dental Therapeutics and Stomatology, 2005.
- Charles M. Cobb AAP-Commissioned Review Lasers in Periodontics: A Review of the Literature, J Periodontol 2006;77:545-564.
- Eberhard J, Ehlers H, Falk W, Acil Y, Albers HK, Jepsen S. Efficacy of subgingival calculus removal with Er:YAG laser compared to mechanical debridement: An in situ study. J Clin Periodontol 2003;30: 511-518.
- Tomasi C, Schander K, Dahlen G, Wennstrom JL. Short-term clinical and microbiologic effects of pocket debridement with an Er:YAG laser during periodontal maintenance. J Periodontol 2006;77:111-118.
- Crespi R, Barone A, Covani U. Er:YAG laser scaling of diseased root surfaces: A histologic study. J Periodontol 2006;77:218-222.
- Gaspirc B., Skaleric U. Clinical Evaluation of Periodontal Surgical Treatment With an Er:YAG Laser: 5-Year Results, J Periodontol, 2007; 78 (10):1864-187.1.
- Cozean C, Arcoria CJ, Pelagalli J, Powell GL. Dentistry for the 21st century? Erbium:YAG laser for teeth. J Am Dent Assoc 1997;128:1080-1087.
- Keller U, Hibst R. Effects of Er:YAG laser in caries treatment: A clinical pilot study. Lasers Surg Med 1997;20:32-38.
- Matsumoto K, Nakamura Y, Mazeki K, Kimura Y. Clinical dental application of Er:YAG laser for Class V cavity preparation. J Clin Laser Med Surg 1996;14:123-127.
- Lee D.H. Application of Laser in Periodontics: A New Approach in Periodontal Treatment. Dental Bulletin, Hong Kong Medical Diary. 2007 Oct, 12(10):23-27.
- Colluzzi DJ. Using lasers for phase one periodontal therapy, Dentistry Today, 124-129, 2007.
- Irinakis. The use of laser for periodontal debridement: Marketing tool or proven therapy. JCDA, 71:653-658, 2005.
- Charles M. Cobb. AAP-Commissioned Review, Lasers in Periodontics: A Review of the Literature. J Periodontol 2006;77:545-564.
- Peng T.K. Clinical Application of YSGG in Periodontology and Oral Implantology, 2007 Congress of Asia Pacific Laser Institute, Taipei, July 20-22, pp. 37.
- Peng TK. Clinical Application of Er:YAG in Implant Patients, 1st International Dental Implant Conference In Taiwan 2008.
- Folwaczny M, Mehl A, Haffner C, Benz C, Hickel R. Root substance removal with Er:YAG laser radiation at different parameters using a new delivery system. J Periodontol 2000; 71(2):147-55.841.
- Ritz L, Hefti AF, Rateitschak KH. An in vitro investigation on the loss of root substance in scaling with various instruments. J Clin Periodontol 1991; 18(9):643-7.
- Zappa U, Smith B, Simiona C, Graft H, Case D, Kim W. Root surface removal by scaling and root planing. J Periodontol 1991; 62(12):750-4.
- Frentzen M, Braun A, Aniol D. Er:YAG laser scaling of diseased root surfaces. J Periodontol 2002; 73(5):524-30.
- Aoki A, Ando Y, Watanabe H, Ishikawa I. In vitro studies on laser scaling of subgingival calculus with an Erbium:YAG laser. J Periodontol 1994; 65(12):1097-106.

HIGH TECH **DENTISTRY**

LASER DENTISTRY

ER:YAG LASERS



#### **About the author**

Tzi Kang Peng is Chairman and Professor of the Department of Dentistry, Cheng Hsin Rehabilitation Medical Center, School of Dentistry, National Defense Medical Center, Taiwan. He is a Diplomat, International Congress of Oral Implantologists; Past President, Taiwan Academy of Periodontology; Past President, Academy of Oral Implantology-ROC; Vice President and Director, Committee of Scientific Committee 2006 24th World Congress, ICOI; and a consultant to the Taiwan Academy of Implant Dentistry; the Taipei Congress of Dental Implantology; the Academy of Oral Implantology-ROC; and the Taiwan Academy of Laser Dentistry.